

# Spontaneous Rib Fracture Improved with Callus Following Acute Severe Cough in Pregnancy

Eurasian Clinical and Analytical Medicine **Original Image**

## Spontaneous Rib Fracture

Rasih Yazkan

Department of Thoracic Surgery, Faculty of Medicine, Süleyman Demirel University, Isparta, Turkey

Fracture healing is an exceptional wound healing response in which the repair process takes place with production of new bone tissue. There are three consecutive and interconnected phases, these phases are inflammatory response, repair and remodeling phases [1]. Coughing is usually self limited and uncomplicated but sometimes can be with complications, one of these complications is rib fracture. Cough induced rib fracture was reported in the literature due to the chronic obstructive pulmonary disease [2]. In this report, we present a case of spontaneous rib fracture improved with callus following acute severe cough in pregnancy. A 42 year old female presented to our department with left posterolateral chest pain, the patients have had acute pneumonia with severe coughing attacks simultaneously chest pain in the eighth month of pregnancy. On physical evaluation, she had seriously tenderness and felt hard callus over her left lower chest wall. There was no history of any thoracic trauma. A chest x-ray revealed but not detected any fracture, a chest computed tomography revealed spontaneous fracture of the left ninth and tenth rib with callus (Figure 1, 2). The Patient was followed with analgesic treatment and not observed any complications in follow up. In conclusion; Cough induced rib fractures is a rare complication during pregnancy. Repetitive mechanical stress due to the high intrathoracic and intraabdominal pressure during pregnancy may be the risk factors due to coughing.

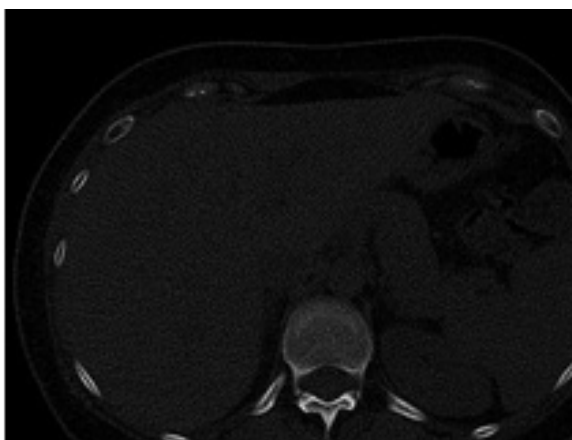


Figure 1. The left ninth rib fracture with callus

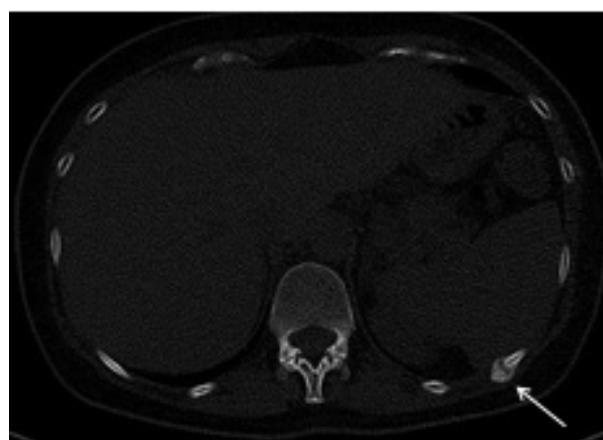


Figure 2. The left tenth rib fracture with callus

### References

1. Yorgancıgil H. .Kırık İyileşmesi. İnönü Üniversitesi Tıp fakültesi Dergisi 2001; 8(2):104-6
2. Yazkan R, Tomruk Ö, Beceren NG. Cough Induced Rib Fracture: A Very Rare Case. JCAM 2012;2: DOI: 10.4328/JCAM. 668

DOI:10.4328/ECAM.54

Received : 08.05.2015

Accepted : 23.05.2015

Published Online : 24.05.2015

Printed Online : 24.05.2015

**Eu Clin Anal Med 2015;3(2): DOI:10.4328/ECAM.54**

**Corresponding Author:** Rasih Yazkan, Göğüs Cerrahisi ABD, Tıp Fakültesi, Süleyman Demirel Üniversitesi, Isparta, Türkiye.

**GSM:** +90 505 483 59 61 - **E-Mail:** drrashiyazkan@yahoo.com

**How to cite this article:** Rasih Yazkan. Spontaneous rib fracture improved with callus following acute severe cough in pregnancy. Eu Clin Anal Med 2015;3(2): DOI: 10.4328/ECAM.54.